

ORIGINAL ARTICLE

Spectrum of Liver Elastography Findings in Various Liver Diseases: Experience from a Single Institution in Sylhet Region, Bangladesh

Mohammed Mehedi Al Zahid Bhuiyan¹, Kamrun Nahar¹, Md Azzad Mia¹,
Muhammad Sirazul Munir¹

ABSTRACT

Accurate staging of liver fibrosis is crucial for prognosis, treatment prioritization, and disease monitoring in chronic liver disorders. Shear wave elastography (SWE) is a non-invasive ultrasound-based technique that quantitatively assesses liver stiffness and is increasingly used as a cross-sectional, descriptive study was conducted on 135 patients referred for liver elastography, between July 2020 and August 2022, to evaluate the pattern of liver diseases and corresponding SWE findings among patients referred to the Institute of Nuclear Medicine and Allied Sciences (INMAS), Sylhet, Bangladesh. Shear wave elastography (SWE) was performed according to the updated Society of Radiologists in Ultrasound (SRU) Liver Elastography Consensus guidelines. Demographic data, clinical indications, biochemical parameters, ultrasonographic findings, and SWE categories were analyzed. The mean age of the participants was 41.71±13.71 years, with a male predominance (52.6%). Most patients (74.8%) were below 50 years age group. Non-alcoholic fatty liver disease (NAFLD) was the most common referral diagnosis (30.4%), followed by chronic hepatitis B virus infection (23.7%). Elevated alanine aminotransferase (ALT) levels were observed in 50.4% of patients. Fatty liver change was the most frequent ultrasonographic finding (41.5%). SWE showed that 42.9% of patients belonged to category 2 liver stiffness, while 11.85% had values suggestive of advanced fibrosis. Shear wave elastography is a reliable, rapid, and non-invasive tool for liver fibrosis assessment and may significantly reduce the need for liver biopsy in routine clinical practice.

Keywords: Shear wave elastography, chronic liver disease, non-alcoholic fatty liver disease

International Journal of Human and Health Sciences Vol. 10 No. 03 July'26

DOI: <https://doi.org/10.31344/ijhhs.v10i3.958>

INTRODUCTION

Chronic liver diseases are a major cause of global morbidity and mortality, accounting for a substantial healthcare burden worldwide. Progressive hepatic fibrosis is a key determinant of clinical outcomes in chronic liver disease, influencing prognosis, therapeutic decision-making, and the risk of complications such as cirrhosis and hepatocellular carcinoma. Accurate assessment of liver fibrosis is therefore crucial for effective disease management and long-term follow-up. Although liver biopsy remains the reference standard for fibrosis staging, its invasive nature, risk of complications, sampling

variability, and limited patient acceptability restrict its routine use in clinical practice.^{1,2}

In recent years, non-invasive imaging techniques have gained increasing importance for the evaluation of liver fibrosis. Shear wave elastography (SWE) enables quantitative and reproducible assessment of liver stiffness by measuring shear wave propagation through hepatic tissue. Multiple validation studies have demonstrated that SWE is a reliable non-invasive method for fibrosis staging in patients with chronic liver disease of various etiologies, including viral hepatitis and metabolic liver disorders.³⁻⁵ As a result, SWE has been incorporated into several

1. Institute of Nuclear Medicine & Allied Sciences (INMAS), Sylhet-3100, Bangladesh.

Correspondence to: Dr. Mohammed Mehedi Al Zahid Bhuiyan, Institute of Nuclear Medicine and Allied Sciences (INMAS), Sylhet-3100, Bangladesh. Email: zahidssmc36@gmail.com

international clinical practice guidelines as an alternative or adjunct to liver biopsy.

The global burden of nonalcoholic fatty liver disease (NAFLD) continues to rise, driven by increasing prevalence of obesity, diabetes mellitus, and metabolic syndrome. NAFLD has emerged as a leading cause of chronic liver disease and is now recognized as an important public health concern in both developed and developing countries. This growing disease burden highlights the need for accessible, accurate, and patient-friendly non-invasive diagnostic tools for early detection and fibrosis assessment.^{6,7}

Under the circumstances, the present study aimed to describe the pattern of liver diseases and corresponding shear wave elastography findings among patients referred to the Institute of Nuclear Medicine and Allied Sciences (INMAS), Sylhet, Bangladesh.

METHODS

This cross-sectional, descriptive study was conducted between July 2020 and August 2022, at Institute of Nuclear Medicine and Allied Sciences (INMAS), Sylhet, Bangladesh. A total of 135 patients referred for liver elastography aged between 18 and 80 years were included in the study. Demographic characteristics, clinical diagnoses, biochemical parameters (including alanine aminotransferase), and ultrasonographic findings were recorded. Shear Wave Elastography (SWE) was performed according to the Society of Radiologists in Ultrasound Liver Elastography Consensus Statement.³ Ten valid measurements were obtained at least 2 cm below the liver capsule, with an interquartile range-to-median ratio $\leq 30\%$, ensuring measurement reliability.^{3,8} To produce shear waves in an object, current commercial systems for measuring shear waves begin by applying force to the object using either a mechanical piston or ultrasound waves. The force is directed perpendicular to the skin's surface, transmitted to the target object, and part of it then disperses parallel to the object's surface as a shear wave. The speed of this shear wave is then measured, which is used to compute Young's modulus.⁹

Data was collected, compiled, coded and analyzed using IBM SPSS Statistics for Windows, version 25 (IBM Corp., Armonk, NY, USA). Data was expressed in frequency and percentages. Data was presented in the tabulated form and pie chart.

RESULTS

A total of 135 referred patients aged between 18 and 80 years were included in this study. The mean age of the study participants was 41.71 ± 13.71 years. Male patients constituted 52.6% of the study population, and the majority (74.8%) were below 50 years of age. According to BMI, 44.4% were within normal limit, 8.1% were underweight, 35.6% were overweight and 11.9% were classified as obese (Table 1). Initial clinical diagnoses were available in 64.4% of patients. NAFLD was the most common indication for referral (30.4%), followed by chronic hepatitis B virus infection (23.7%) and chronic liver disease of various etiologies (8.9%). Elevated levels of ALT were observed in 50.4%, while 34.1% had values within the normal range (Table 2). Conventional 2D ultrasonography revealed fatty liver changes as the most common finding (41.5%), followed by coarse hepatic parenchyma (26.7%) (Table 3). Based on SWE measurements, the majority of the patients (42.9%) belonged to the category 2 liver stiffness (< 1.7 m/s), suggesting mild fibrosis. Category 3 stiffness values (1.7–2.1 m/s) were found in 20%, while 11.9% demonstrated values > 2.1 m/s, consistent with advanced fibrosis or cirrhosis (category 5) (Figure 1).

Table 1: Demographic characteristics of the study patients (n=135)

Variables	Frequency	Percentage
Age group		
≤ 50 years	101	74.8
50 years	34	25.2
Gender		
Male	71	52.6
Female	64	47.4
BMI		
Normal	60	44.4
Underweight	11	8.1
Overweight	48	35.6
Obese	16	11.9

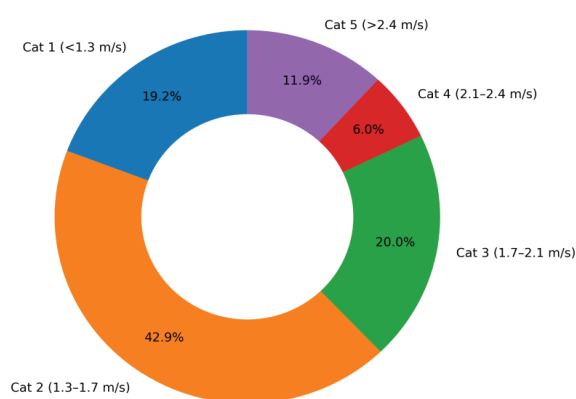
Table 2: Clinical characteristics of the study patients (n=135)

Variables	Frequency	Percentage
Provisional diagnosis		
Non-alcoholic fatty liver disease (NAFLD)	41	30.4
Chronic hepatitis B	32	23.7
Chronic liver disease	12	8.9
Others	50	37.0
Serum ALT		
Normal	46	34.1
Elevated	68	50.4
Report not found	21	15.5

Table 3: 2D ultrasonogram findings of the hepatic system (n=135)

Ultrasonographic findings	Frequency	Percentage
No sonographic abnormality	24	17.8
Coarse hepatic parenchyma	36	26.7
Fatty change in liver	56	41.5
Fatty change with coarse hepatic parenchyma	9	6.7
Coarse hepatic parenchyma with splenomegaly and ascites	2	1.5
Hepatosplenomegaly	2	1.5
Coarse hepatic parenchyma with splenomegaly	5	3.7
Hepatosplenomegaly with ascites	1	0.7

Distribution of Liver Fibrosis Stages by Shear Wave Elastography (n = 135)

**Figure 1:** Distribution of stages of liver fibrosis by shear wave elastography (n=135).

DISCUSSION

This study highlights the clinical applicability of shear wave elastography (SWE) as a non-invasive modality for assessing liver fibrosis in patients with diverse liver diseases. No matter the initial cause, repeated injury to the liver results in fibrosis, which can ultimately progress to cirrhosis. If the cause of fibrosis is addressed promptly, it is possible for fibrosis to be reversed. In cases of cirrhosis, improvement can occur, although complete reversal is not achievable, leading to better clinical outcomes. Traditionally, liver biopsies have been the main approach to assess and confirm the extent of liver fibrosis.² However, shear wave elastography offers a

non-invasive way to evaluate liver stiffness, potentially allowing for earlier detection when reversal is still feasible. Additionally, increased liver stiffness without organic liver disease may indicate early organ damage due to various factors, thus allowing for timely interventions to help slow disease progression.⁸⁻¹⁰

The predominance of nonalcoholic fatty liver disease among referred patients reflects the increasing burden of metabolic liver disease, consistent with regional and global epidemiological trends.^{6,7} The observed distribution of liver stiffness categories indicates that a substantial proportion of patients had mild to moderate fibrosis, underscoring the importance of early detection and timely intervention. The identification of advanced fibrosis in a notable subset of patients demonstrates the value of SWE in risk stratification and clinical decision-making.^{3,8-10}

Biochemical parameters such as alanine aminotransferase showed limited concordance with fibrosis severity, supporting previous reports that liver enzyme levels alone may not reliably reflect underlying structural liver changes.^{1,2} In contrast, SWE provides objective and reproducible measurements, complementing conventional ultrasonography and laboratory investigation.^{3-5,11} Overall, the findings of this study are consistent with existing literature validating SWE as an effective tool for fibrosis staging. Routine incorporation of SWE into clinical practice may facilitate longitudinal disease monitoring, reduce reliance on invasive liver biopsy, and improve patient compliance, particularly in resource-limited settings.^{3,4,10-12}

CONCLUSION

Shear-wave elastography serves as a sensitive marker for liver damage caused by different factors. While it has limitations in identifying the specific cause, it is effective in differentiating the severity of the injury. This technique is fast, dependable, and non-invasive, making it suitable for assessing liver fibrosis in patients with chronic liver diseases. Regular implementation of this method in clinical settings could greatly decrease the necessity for liver biopsies, enhance patient adherence, and assist healthcare providers in making timely decisions, especially in environments heavily affected by NAFLD and viral hepatitis.

Conflict of interest: None declared by the authors.

Funding statement: Self-funded.

Ethical approval: The study was approved by the Ethics Review Committee of the Institute of Nuclear Medicine and Allied Sciences (INMAS), Sylhet, Bangladesh.

Authors' contribution: Conceptualization and design of the study: MMA Bhuiyan; patient selection, data collection, compilation and analysis: MMA Bhuiyan, K Nahar, MA Mia, MS Munir; manuscript preparation, editing and final submission: MMA Bhuiyan, K Nahar, MA Mia, MS Munir.

REFERENCES

1. Gleeson J, Barry J, O'Reilly S. Use of liver imaging and biopsy in clinical practice. *N Engl J Med.* 2017;377(23):2296.
2. Rockey DC, Caldwell SH, Goodman ZD, Nelson RC, Smith AD; American Association for the Study of Liver Diseases. Liver biopsy. *Hepatology.* 2009;49(3):1017-44.
3. Barr RG, Wilson SR, Rubens D, Garcia-Tsao G, Ferraioli G. Update to the Society of Radiologists in Ultrasound Liver Elastography Consensus Statement. *Radiology.* 2020;296(2):263-74.
4. European Association for Study of Liver; Asociacion Latinoamericana para el Estudio del Hgado. EASL-ALEH Clinical Practice Guidelines: non-invasive tests for evaluation of liver disease severity and prognosis. *J Hepatol.* 2015;63(1):237-64.
5. Ferraioli G, Wong VW, Castera L, Berzigotti A, Sporea I, Dietrich CF, et al. Liver ultrasound elastography: an update to the World Federation for Ultrasound in Medicine and Biology Guidelines and Recommendations. *Ultrasound Med Biol.* 2018;44(12):2419-40.
6. Younossi ZM, Golabi P, Paik JM, Henry A, Van Dongen C, Henry L. The global epidemiology of nonalcoholic fatty liver disease (NAFLD) and nonalcoholic steatohepatitis (NASH): a systematic review. *Hepatology.* 2023;77(4):1335-47.
7. Wong VW, Adams LA, de Lédinghen V, Wong GL, Sookoian S. Noninvasive biomarkers in NAFLD and NASH – current progress and future promise. *Nat Rev Gastroenterol Hepatol.* 2018;15(8):461-78.
8. Friedrich-Rust M, Ong MF, Martens S, Sarrazin C, Bojunga J, Zeuzem S, et al. Performance of transient elastography for the staging of liver fibrosis: a meta-analysis. *Gastroenterology.* 2008;134(4):960-74.
9. Chen CM, Tang YC, Huang SH, Pan KT, Lui KW, Lai YH, et al. Ultrasound tissue scatterer distribution imaging: an adjunctive diagnostic tool for shear wave elastography in characterizing focal liver lesions. *Ultrason Sonochem.* 2023;101:106716.
10. Suffredini G, Gao WD, Dodd-O JM. Ultrasound shear wave elastography evaluation of the liver and implications for perioperative medicine. *J Clin Med.* 2024;13(13):3633.
11. Castera L, Vilgrain V, Angulo P. Noninvasive evaluation of NAFLD. *Nat Rev Gastroenterol Hepatol.* 2013;10(11):666-75.
12. Loomba R, Adams LA. The 20% rule of NASH progression: the natural history of advanced fibrosis and cirrhosis caused by NASH. *Hepatology.* 2019;70(6):1885-8.